

SECTION 4

Taking cervical smears

	Page	Issue date
4.1 The importance of the smearer	1	Oct 08
4.2 The smearing process	1	Oct 08
4.3 Managing difficulties that may arise when taking a smear	31	Oct 08
Appendix	34	Oct 08
The Cervical Cytology Form	35	Oct 08
References & further reading	36	Oct 08
Notes	38	

Taking cervical smears

Aim of section

The aim of this section is to deal with the technical and communication skills that ensure a competent smartaker. This Section is designed for new smartakers and those smartakers wishing to maintain competency.

4.1 The importance of the smartaker

One of the most important factors in effective screening programmes is that the screening test and management of the test result are performed competently. The smartaker must learn to harvest the cells of the squamocolumnar junction of the cervix when smartaking and deal with the sample and each woman appropriately. Moreover, it is important that the woman has a positive experience every time she attends for cervical screening.

See this Section at 4.2F & Section 6 for further information on consultation & communication

In order that a woman can make informed decisions about participation in screening, it is important that she has a sufficient understanding of cervical cancer and the risks and benefits of screening. Ensuring that each woman understands the purpose and procedures involved in cervical screening is an essential task for smartakers. In addition to ensuring a quality clinical environment the smartaker has a key role in communicating issues of consent and confidentiality.

4.2 The smartaking process

This Section considers the technical and practical process of smartaking and covers the following areas.


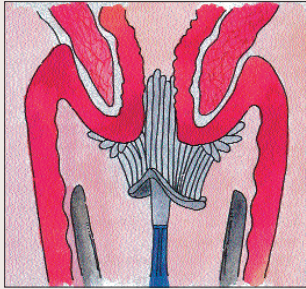
KEY AREAS FOR THE SMEARTAKER TO CONSIDER	KEY POINTS
A. The smear test procedure	<ul style="list-style-type: none"> Poor techniques can result in 20 per cent or more of pre-cancerous abnormalities being missed. An inadequate sample may result in a negative report or a report of dyskaryosis, which underestimates the degree of abnormality present.
B. Locating and visualising the cervix	
C. Assessment of the cervix	
D. Cervical Cytology Form	
E. Anatomy and physiology	
F. Consultation	
G. Environment and equipment	



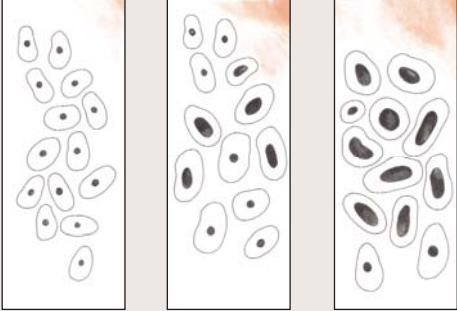
4.2A The smear test procedure

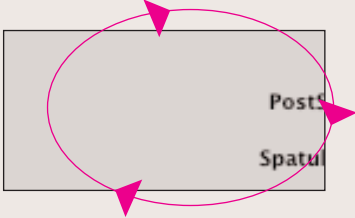
STAGE OF PROCEDURE	KEY POINTS
<p>Chaperone In Ireland, the Irish Medical Council guidelines for doctors states that any intimate examination should be accompanied by an explanation and the patient, irrespective of age or gender, should be offered a chaperone.</p> <p>Before the test The smearer should ensure that the necessary supplies and equipment are ready (<i>see Section 4.2G</i>). An appropriate history taking and consultation with the woman is undertaken (<i>see Sections 4.2D & 6</i>) and any individual special requirements should be accommodated. The woman should be allowed an opportunity to empty her bladder.</p>	<p>There are on-going studies in the area of 'chaperone provision' particularly with reference to the primary care setting. A sensible and flexible approach is recommended (Rosental, 2005).</p> <p>The smearer should wash his/her hands before and after any procedure which involves close contact with the patient.</p>
<p>Background to examination The 'cervix' as the name suggests is the 'neck' of the uterus. It is usually situated high in the vagina and is identified as a firm cylindrical structure with an opening into the endocervical canal.</p> <p>The smearer should sample all of the vulnerable area of the cervix and should transfer all of the harvested cells to the laboratory. The vulnerable area is the junction between the thick resilient squamous epithelium of the ectocervix and the thin columnar epithelium that lines the endocervix and everts outwards at stages in a woman's life. The everted area will over time transform from thin columnar epithelium to thicker tougher squamous epithelium. The area changing is the transformation zone.</p> <p>This is the area where metaplastic change occurs (<i>see Section 3</i>).</p> <p>The cervix brush (Cervex-Brush®) is used to remove cells from the cervix and these cells must reach the laboratory in a condition that allows the cells to be examined.</p>	<p>The test is to check for abnormal cells that if left untreated may turn cancerous. It is not a test for cancer. It does not tell anything about the ovaries or uterus.</p> <p>Explain to the woman what you are doing at each stage and check that she understands e.g. <i>"I need to take the sample from the right place on your cervix. I will hold back the vaginal walls with this speculum in order to get a good look at the cervix."</i></p>

4.2A The smear test procedure contd.

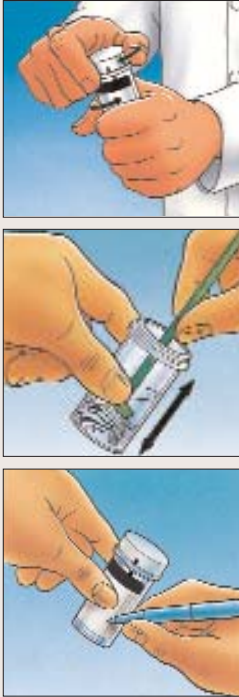

STAGE OF PROCEDURE	KEY POINTS
<p>Ideal Conditions for a Test</p> <p>The best time for a smear to be taken is between the 7th and 15th day of the menstrual cycle to facilitate optimal cytological conditions and when it is unlikely there will be any remaining menstrual blood (Vooijs, 1987). However, this does not mean that a smear cannot be taken at a different time in a woman's cycle but should be avoided if there is menstrual blood present.</p>	<p>All women making appointments for a smear test need to be advised that the optimal time for the test is mid cycle - that is approximately fourteen days after the start of menstruation. Reception staff should be made aware of this.</p>
<p>Type of test used</p> <p>The single test for smears taken in Ireland is liquid-based cytology (LBC). The sampling tool is the Cervex-Brush®. The transport medium is a liquid-filled vial.</p> <p>The Aylesbury spatula and the narrow 'chimney sweep' brush are NOT recommended for use. The endocervical brush is sometimes used in a colposcopy setting.</p>	<p>Figure 4.1 Vial and Cervex-Brush®</p>  <p>Kind permission to use images received from Hologic Inc.</p> <p>Figure 4.2 Cervex-Brush® in Cervix</p>  <div data-bbox="906 1814 1423 1982"> <p>Cervix os →</p> <p>Cervex-Brush® →</p> </div>

4.2A The smear test procedure contd.

STAGE OF PROCEDURE	KEY POINTS
<p>What smertakers need to understand about the test</p> <p>Liquid-based cytology allows for separation of cervical cells from blood, mucus and non-diagnostic debris in the laboratory by a spinning process and a slide is then made from the harvested cervical cells. The filters can be blocked by excessive debris or lubricant.</p>	<p>Figure 4.3 Slide made with LBC harvested cells</p>  <p>Showing normal cells</p> <p>Dyskaryotic cells with large nuclei</p>

<p>Taking the sample</p> <p>See 4.2B and 4.2C of this Section for information on insertion of the speculum, the visualisation, assessment and interpretation of the cervical findings. Having visualised the entire cervix and identified the squamocolumnar junction, the long central bristles of the Cervex-Brush® are inserted into the external cervical os, ensuring good contact is made. The smertaker should sweep the brush around the whole transformation zone including the margins.</p> <p>It is important that the sample is taken with care so that the Cervex-Brush® is firmly rotated to a full 360 degrees, <u>five</u> times in a <u>clockwise</u> direction. This should be done using 'pencil' pressure by rolling the stem between the thumb and the forefinger, ensuring that the lateral bristles bend against the ectocervix and maintain good contact throughout.</p> <p>Copious cervical mucous can be removed before taking the smear by gently twisting the other end of the Cervex-Brush® in the mucous, avoiding contact with the cervix, and then 'lifting' the mucous off the cervix.</p>	<p>It is vital to rotate in a clockwise direction as the plastic bristles are bevelled and only harvest cells when rotated in this direction.</p> <p>The smertaker must visualise the cervix and sample the whole circumference of the cervical os, including the transformation zone.</p> <p>If it is necessary to take a swab for purposes other than the smear test, it must be taken <u>after</u> the smear test. It is usual to advise the woman that a swab has been taken in addition to the smear test and will require separate follow up.</p> <p>Figure 4.4 Rotation of Cervex-Brush®</p>  <p>Five times in a <u>clockwise</u> direction</p>
--	---

4.2A The smear test procedure contd.

STAGE OF PROCEDURE	KEY POINTS
<p>Preparation of sample for the laboratory</p> <p>The cells need to be transferred directly into the liquid and this is done immediately with vigorous “<i>mash and bash</i>” action to ensure maximum yield. It is recommended that the bristles of the brush are pushed vigorously against the bottom of the specimen vial ten times, ensuring that the bristles are pushed apart. It should look distorted when the sample has been prepared.</p> <p>The Cervex-Brush® should then be rinsed by rotating the shaft of the brush between the finger and thumb and should be inspected for any residual material. Any remains should be removed by passing the brush over the edge of the vial but do not stand Cervex-Brush® in liquid at any time.</p> <p>The cap should be tightened, but not over-tightened, so that the line on the cap passes the torque line on the vial. The vial can be shaken if any material has been placed on the edge of the vial. The Cervex-Brush®/ sampler may then be discarded with the clinical waste.</p>	<p>Lights in a surgery are hot and can quickly dry samples, making them unreadable in the laboratory.</p> <p>The vial should be prepared immediately and not left standing while dealing with the speculum, woman or the Cervical Cytology Form.</p> <p>In order to be accepted at the laboratory, a slide or vial must contain at a minimum: the woman's surname, first name / initial and date of birth. These details must all exactly match the details on the Cervical Cytology Form.</p> <p>Figure 4.5 Preparing sample for laboratory</p>  <p>Kind permission to use images received from Hologic Inc.</p>
<p>Submitting samples to the laboratory</p> <p>Liquid based cytology vials must be posted within five working days, even if the transport box is not full.</p> <p>Boxes are reusable and should not be written on. It is advisable to log the day of posting the smear and one 'bar code' label should be retained when posting to allow for tracing in the event that a package is lost in transit.</p>	<p>Best practice is to dispatch the sample on the day it is taken.</p> <p>Figure 4.6 Vial in transport box</p> 

SUMMARY	KEY POINTS
<ol style="list-style-type: none"> 1. Write the woman's identification details on the Cervical Cytology Form and the liquid base vial. 2. Choose the appropriate speculum for the woman. 3. Identify and visualise the cervix. 4. Take a sample from the entire squamocolumnar junction. 5. Rinse the cells immediately into the LBC vial and cap. 6. Put into a suitable transport container. 7. Record details of the smear on the Cervical Cytology Form and in the woman's clinical notes. 8. Enter the smear in a practice tracking system, manual or electronic. 9. Post promptly to the laboratory to minimise turnaround time. 	<p>The smearer should wash his/her hands before and after any procedure involving close contact with the patient.</p> <p>In order to take an adequate sample the cervix must be visualised in its entirety.</p> <p>Attention to detail is of vital importance to ensure a quality smear.</p> <p>Poor sampling may lead to failure to detect abnormalities.</p> <p>A negative or inadequate smear can occur in invasive cancer of the cervix and endometrial cancer. If the smearer suspects invasive cancer on inspection of the cervix, urgent referral is recommended to the local gynaecologist without waiting for the result of the smear test.</p> <p>Ensure that all results are received and recommendations acted upon.</p> <p>Responsibility for posting the smear lies with the smearer.</p>

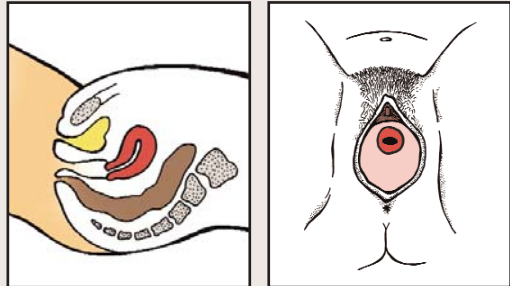
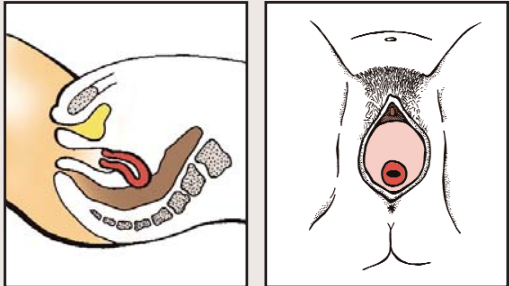
Message for woman

No test is 100 per cent accurate. This is why regular screening is important. Any abnormal bleeding or discharge needs to be reported to the doctor even with a recent normal smear test.

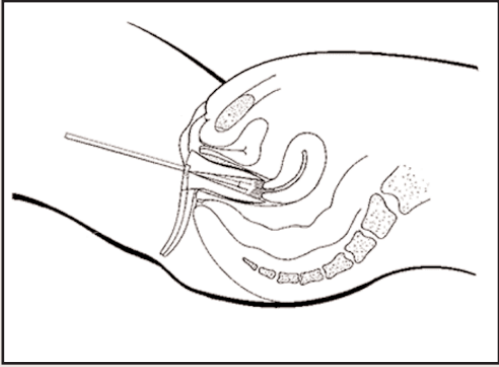
4.2B Location and visualising the cervix

STAGE OF PROCEDURE	KEY POINTS
<p>Prepare the woman</p> <p>Ask the woman to undress to the waist behind the screened area and to lie on the couch. The woman may be more comfortable leaving her skirt on but removal of trousers is needed to allow for adequate exposure and good lighting of the perineum. Ensure that privacy is maintained by using a couch roll as a cover rather than a blanket or sheet where infection control could be compromised.</p> <p>The position of the woman is important and the time spent ensuring she is in the correct position will make finding the cervix easier. The woman should be asked to bend her knees while keeping her feet together.</p> <p>Smear tests can be taken in the dorsal position or in the left lateral position. The dorsal position allows for better communication and observation of the woman and is the most common position to take a smear. In the dorsal position, the woman lies with the buttocks towards the light source, soles of feet together, knees bent and legs lax but wide open. If there is difficulty when smertaking, it can be effective to reposition the woman and for her to place her fists under her buttocks.</p> <p>Some women may be used to having smears taken in the left lateral position and may put themselves in that position. The left lateral position may be better for visualising the cervix if the uterus is acutely anteverted or retroverted.</p>	<p>It is important to help the woman to relax. For some women, explanation of the various steps in the procedure helps them to relax.</p> <p>A confident, unrushed demeanour is helpful and good practice recommends that the first touch to the woman should be on her arm or leg by way of reassurance.</p> <p>Figure 4.7a Positioning of the woman - dorsal</p>  <p>Figure 4.7b Positioning of the woman - left lateral</p> 
<p>Choose a speculum</p> <p>A tray or trolley with the appropriate equipment and full range of speculae should be close at hand. When choosing a speculum, the age, parity and size of the woman should be taken into consideration.</p> <p>If using a disposable speculum, the package should not be opened until ready for use. When using reusable speculae, a range of sizes should be available and in a sterile state.</p>	<p>Ensure used or non-sterile instruments are kept separate from clean/sterile instruments.</p> <p>Figure 4.8 Speculae - different sizes</p> 


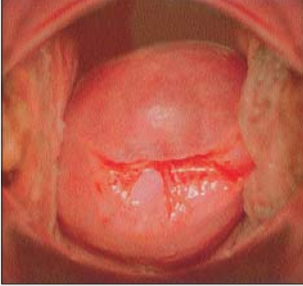

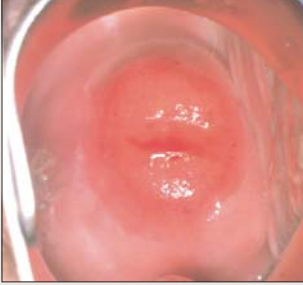
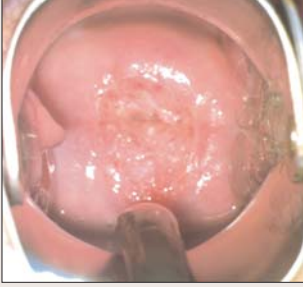
4.2B Location and visualising the cervix contd.

STAGE OF PROCEDURE	KEY POINTS
<p>Position of the light</p> <p>Good lighting is vital in finding and assessing the cervix and taking a smear test. Wall-mounted or floor standing lights with halogen bulbs are recommended. The light source should be angled to allow clear visualisation of the cervix and vaginal walls and should be adjusted as necessary during the course of the procedure. A speculum light (a small bright light source that can be attached to the speculum) can be helpful.</p> <p>To prevent contamination, the light should be handled with a paper towel or elbowed out of the way, when gloved.</p>	<p>It is important that the smearer moves away from the light when transferring the cells as strong lighting can cause cells to dry out before fixing them in the liquid.</p>
<p>What to understand about locating the cervix</p> <p>Finding the cervix and visualising it in its entirety is not always easy. In some women after introducing a speculum the cervix is very obvious, in others it is more difficult to find and inspect.</p> <p>An anteverted uterus is the usual position for the uterus where the cervix tilts slightly backward. Less common is the uterus that is retroverted where the cervix lies behind the pubic bone or anteriorly in the vagina.</p> <p>Some women have small tight vaginas, some (usually those who have had vaginal deliveries) will have larger vaginas and some due to loss of muscular tone will have 'floppy' vaginal walls that can make it difficult to visualise the cervix.</p>	<p>The smear should not be taken if the smearer is unable to identify and visualise the entire cervix.</p> <p>Figure 4.9a Anteverted uterus</p>  <p>Figure 4.9b Retroverted uterus</p> 



4.2B Location and visualising the cervix contd.

STAGE OF PROCEDURE	KEY POINTS
<p>Insertion of the speculum</p> <p>The largest size speculum that can be comfortably inserted should be chosen. The appropriate size will be helpful in holding back the vaginal walls. A long speculum is usually required for tall women. It can also be useful when the cervix is in a posterior position. In obese women, or women with a lax vagina, sheathing the speculum with a cylinder cut from the finger of a large surgical glove may prevent the vaginal walls from obscuring the cervix.</p> <p>The smertaker should check the temperature of the speculum and adjust to body temperature. This, however, is not necessary with disposable plastic speculae which are preferred by some women. After inspection of the vulva, the labia should be separated and the speculum inserted gently but firmly along the axis of the introitus, with the speculum pointing downwards and backwards.</p> <p>When the speculum is half way up the vagina, it should be rotated gently through 90 degrees. It is important to angle the speculum towards the patient's coccyx and not to open the speculum until it is fully inserted. Opening and closing the speculum and changing the angle of insertion should bring the cervix into view.</p> <p>A common error is failure to insert the speculum far enough into the vagina. It is helpful to allow a little time after passing the speculum to allow the woman to relax.</p> <p>Lubrication of the speculum is usually not necessary but if the vagina is very dry, a little water or a small amount of soluble lubricant, such as KY Jelly, can be applied. To avoid contaminating the cervix, care must be taken not to place the lubricant on the tip of the speculum. If necessary and with the woman's consent, a gentle digital examination to locate the cervix may be carried out and any vaginal secretions used to lubricate the speculum along its sides. On digital examination, the cervix should feel like the tip of the nose with a firm consistency. Encouraging the woman to relax or cough, tipping her pelvis by asking her to put her fists or a folded towel under the buttocks, may be helpful in bringing the posterior positioned cervix into view.</p>	<p>Message for the woman: <i>"The more relaxed you can be, the easier it will be to find the cervix and take a sample of cells from the right area".</i></p> <p>A woman's request to stop the procedure at any time must be respected.</p> <p>If visualisation proves difficult it may be helpful to start again and re-position the woman. (see 4.3 in this Section)</p> <p>Figure 4.10 Insertion of the speculum</p>  <p>In the clinical notes, record difficulty and any solution that may be helpful on the next occasion e.g. <i>this lady has a retroverted uterus and cervix is found anteriorly in the vagina,- or the cervix very posterior and longest speculum useful, etc.</i></p> <p>If the cervix is present but you cannot visualise it, do not take the smear test.</p>



4.2C Assessment of the cervix

ASSESSMENT	KEY POINTS
<p>The appearance of the cervix</p> <p>Inspection of the vulva and vagina will aid the smearer when assessing the cervix. Viral warts or evidence of a discharge may be visible which may have a direct influence on the assessment and interpretation of the cervical findings.</p> <p>The cervix has a wide range of appearances depending on age, parity, hormonal status, presence of infection and/or previous surgery. Such variety may be confusing and the smearer must become familiar with the different appearances of the normal cervix. It is not possible to identify the presence or absence of cellular abnormalities at the time of smearing and precancerous abnormalities are invisible to the naked eye.</p> <p>The cervix varies in size, shape and also position in the vagina. A nulliparous cervix may be small with a minute opening at the ectocervix and found high in the vagina. A multiparous woman may have a large irregular cervix found low in the vagina. It is vital to visualise and inspect the entire cervix and the transformation zone is the area that should be sampled when taking the smear test (see 4.2E of this Section on Anatomy & Physiology). Microscopic examination of the cells brushed from the epithelium can determine if there is an abnormality or CIN present.</p>	<p>The cervix may look normal even if there is an abnormality present.</p> <div style="display: flex; flex-direction: column; align-items: flex-end;"> <div style="display: flex; align-items: center; margin-bottom: 10px;">  <div style="margin-left: 10px;"> <p>Figure 4.11a Normal cervix</p> </div> </div> <div style="display: flex; align-items: center; margin-bottom: 10px;">  <div style="margin-left: 10px;"> <p>Figure 4.11b Multiparous cervix</p> </div> </div> <div style="display: flex; align-items: center; margin-bottom: 10px;">  <div style="margin-left: 10px;"> <p>Figure 4.11c Cervical eversion (Ectropion)</p> </div> </div> <div style="display: flex; align-items: center; margin-bottom: 10px;">  <div style="margin-left: 10px;"> <p>Figure 4.11d Normal cervix - eversion undergoing change into Squamous Epithelium in the Transformation Zone</p> </div> </div> <div style="display: flex; align-items: center;">  <div style="margin-left: 10px;"> <p>Figure 4.11e View of normal cervix eversion almost completely transformed into squamous epithelium</p> </div> </div> </div>

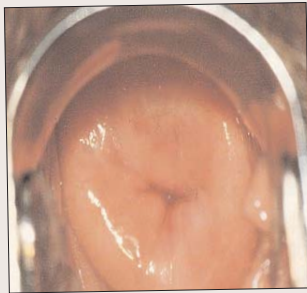

4.2C Assessment of the cervix contd.

ASSESSMENT	KEY POINTS
<p>Bleeding when taking the test</p> <p>Contact bleeding when screening is not uncommon and liquid based cytology can remove some red blood cells.</p> <p>Chlamydia infection can be a cause of bleeding at the time of the smear test and any swabs taken if required for diagnosis should be taken after the smear test and not before.</p>	<p>It is recommended that the best time to take a smear test is mid-cycle and menstrual smears should not be taken.</p> <p>STI screening is not part of the cervical screening process.</p>
<p>Cervical mucous</p> <p>The cervix secretes mucous that covers the endocervical canal and the vaginal epithelium. Mucous production is controlled by hormones, with the amount and viscosity changing as the concentration of oestrogen and progesterone change. It is believed that mucous acts in a variety of ways to prevent micro-organisms from colonising and infecting the cervix.</p>	<p>Figure 4.12a Mid-cycle mucous</p>  <p>Figure 4.12b Excess mucous</p>  <p>Excess mucous will obscure the smertaker's view of the entire cervix and interfere with sampling. Gentle removal without touching the cervix is advised.</p>


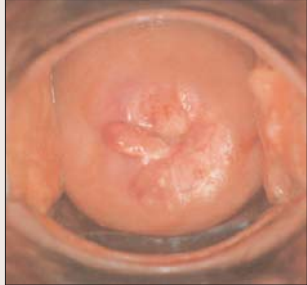

4.2C Assessment of the cervix contd.

PHYSIOLOGICAL CHANGES	KEY POINTS
<p>Common physiological changes</p> <p>Cervical ectropion involves the eversion and migration of cells from the inner lining of the endocervical canal or endocervix to the outer portion of the cervix or ectocervix. An eversion used to be called an erosion or ectropion.</p> <p>Eversion is a physiological change that the cervix undergoes with growth and the influence of hormones. Though large eversions can look alarming, they are common and the smearer might expect to see an eversion if the woman is taking hormonal contraception.</p> <p>If a wide eversion is present, the smearer should use a wide sweeping action around the everted squamocolumnar junction. The cervical sample should include squamous and endocervical cells and cells from the transformation zone.</p>	<p>Figure 4.13 Normal cervix with large eversion (ectropion)</p>  <p>It should be noted that the position of the transformation zone varies during a woman's lifetime. Ref A&P Section 4.2E</p> <p>Figure 4.14 Normal cervix with no eversion noted</p> 

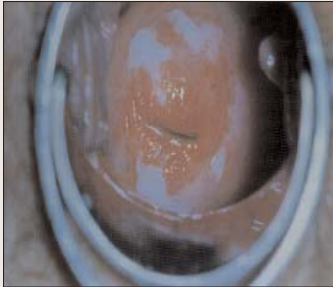
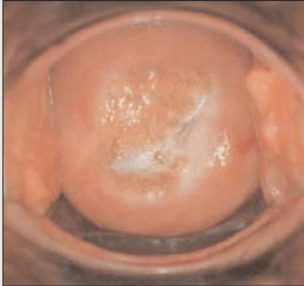
4.2C Assessment of the cervix contd.

PHYSIOLOGICAL CHANGES	KEY POINTS
<p>During pregnancy The cervix during pregnancy is engorged, has a purple hue and may bleed more easily.</p>	<p>Smears during pregnancy are usually not necessary if a woman's previous smears are normal and may be deferred until three months post partum. If the woman does need one there are usually no contra-indications to having one preformed.</p>
<p>Breast feeding Breast feeding mothers who are due a screening smear should be advised that though the smear test is not optimal while breast feeding due to the hormonal changes that occur at this time it is unwise to defer screening indefinitely. It is reasonable to wait until breast feeding is finished but if deferral is > 3 months it is advisable to proceed with the smear test.</p>	<p>Remember some women will breast feed for 2 years, may then become pregnant and so a lengthy delay in screening may ensue.</p>
<p>Post-menopausal The post-menopausal cervix appears shrunken and the squamocolumnar junction having receded into the endocervical canal. The cervix may look pale and dry, and bleed easily. The vagina may be dry or inflamed and is known as 'atrophic vaginitis'. It can be difficult to harvest sufficient cells and may also be difficult to sample the transformation zone. In such circumstances, the smear may be reported as inadequate.</p> <p>In order to take a quality smear in older women, a course of local oestrogen for four weeks (if there are no contraindications) may be needed to allow the columnar epithelium to 'evert'. This will allow the transformation zone to be sampled adequately.</p>	<p>Three inadequate smear tests, for whatever reason, warrant referral for colposcopy. After one inadequate smear result, the older woman should be offered local oestrogen and the smear repeated soon afterwards.</p> <p>The minimum interval for a repeat of an inadequate smear is three months which allows the cells of the cervix to regenerate.</p> <p>Figure 4.15a Post menopausal cervix</p>  <p>Figure 4.15b Post menopausal cervix</p> 



4.2C Assessment of the cervix contd.

PHYSIOLOGICAL CHANGES	KEY POINTS
<p>Anomalies, nabothian follicles & cervical polyps There are a number of physiological changes that the cervix may undergo.</p> <p>Nabothian follicles are mucous filled cysts on the surface of the cervix. They are usually caused when stratified squamous epithelium of the ectocervix grows over the columnar epithelium of the endocervix. The tissue growth can block the cervical crypts, trapping cervical mucous inside the crypts. They are often visible on the cervix at various stages of ripeness.</p> <p>There are two distinct types of cervical polyps: sessile and pedunculated and where present, smears should be taken as usual. Referral for removal may be indicated.</p>	<div style="display: flex; flex-direction: column; align-items: flex-end;"> <div style="display: flex; align-items: center; margin-bottom: 10px;">  <div style="margin-left: 10px;"> <p>Figure 4.16 Nabothian follicles</p> </div> </div> <div style="display: flex; align-items: center; margin-bottom: 10px;">  <div style="margin-left: 10px;"> <p>Figure 4.17 Pedunculated polyp</p> </div> </div> <div style="display: flex; align-items: center;">  <div style="margin-left: 10px;"> <p>Figure 4.18 Sessile polyp</p> </div> </div> </div>

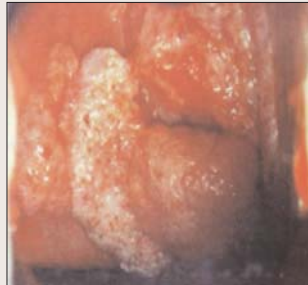
4.2C Assessment of the cervix contd.


NON-CANCEROUS DISEASES & THE CERVIX	KEY POINTS
<p>Infections</p> <p>The vulva and vagina may show evidence of infection and infections can affect the smear result. The vulva vagina may show evidence of infections and infections can affect the smear result. Infections maybe acute or chronic.</p> <p>The cervix can look different to normal because of the presence of infections either viral, bacterial, fungal (moniliasis) or due to the overgrowth of normal organisms with a shift in bacterial flora causing some discharge and inflammation. Inflammation may be present due to mechanical, physical and/or chemical trauma.</p>	<p>A routine smear test is a search for abnormal cervical cells and should not be confused by the presence or management of other clinical conditions.</p> <p>It is important to note that the smertaker is primarily interested in a quality test - the diagnosis and management of infections is outside the scope of this Guide.</p>
<p>Vaginal candida (Moniliasis)</p> <p>Vaginal candida is an overgrowth of a normal organism in the vagina and vulva. The woman may complain of itch. If the infection is severe with a copious, white 'cheesy' discharge and the woman is likely to return for her smear test, it may be more appropriate to treat the candida/thrush infection before proceeding to a smear test.</p>	<p>The likely presence of thrush should be noted on the Cervical Cytology Form.</p> <p>Figure 4.19 Vaginal candida</p> 
<p>Non-specific cervicitis</p> <p>Acute, non-specific cervicitis may result from direct trauma, and/or from the use of douches and ointments. Chronic, non-specific cervicitis is another gynaecological disorder, which may be due in part to a low grade infection in a locally altered cervical environment.</p> <p>Purulent discharge from the cervical os</p> <p>A heavy discharge from the cervical os is distinguished from cervical mucous by the copious amount of discharge, the colour and smell of the discharge and the inflamed appearance of the cervix. A smear test taken while there is cervicitis will be more difficult to interpret due to the obscuring of cervical cells with inflammatory cells. The most prevalent bacterial STI is Chlamydia.</p>	<p>Consideration should be given to identifying and treating an infection before smear testing.</p> <p>Figure 4.20 Purulent discharge</p> 

4.2C Assessment of the cervix contd.

NON-CANCEROUS DISEASES & THE CERVIX	KEY POINTS
<p>Herpes infections</p> <p>Primary infections are usually very painful and it is unlikely that a smear test could be taken. Symptoms of recurrent disease are less severe and herpetic lesions should be noted on the Cervical Cytology Form if identified at the time of smearing.</p>	<p>Figure 4.21 Herpes infection</p> 
<p>Human Papilloma Virus (HPV) & warts</p> <p>HPV produces two types of lesions on the cervix. Clinical condylomata are visible but the sub-clinical, non-condylomatous type is only obvious after the application of acetic acid. Visible warts on the cervix can be flat or proliferative. Warts may be visible on vulva and vaginal walls but not on the cervix.</p> <p>Cytologically, the presence of the Human Papilloma Virus causes a large perinuclear halo and other nuclear changes.</p> <p>Warts are caused by Human Papilloma Virus (see Section 3 of this Guide).</p>	<p>Figure 4.22 Vulval warts</p>  <p>Figure 4.23 Warts on the cervix and vaginal walls</p>  <p>There is no requirement for increased screening if the woman has a history of having genital warts, screening intervals should be on the management recommendations from the laboratory.</p>

4.2C Assessment of the cervix contd.

CANCER OF THE CERVIX	KEY POINTS
<p>Cancerous changes of the cervix</p> <p>Advanced invasive cancer of the cervix is very rarely seen and occasionally, there may be a small area of suspicion. Invasive cancer may be confined initially to only a small area of the cervix and for this reason, the entire cervix must be seen at each smear test. Invasive cancer of the cervix is rarely seen by regular smertakers and if suspected, referral to a gynaecologist is urgently required.</p> <p>A smear taken in this case will probably cause bleeding, but, worryingly, may indeed be reported as normal due to rapidly dividing cells and so is unreliable. There may be a report of inflammation as many types of primary malignant tumours are associated with an inflammatory reaction both within the tumour and in the adjacent stroma.</p>	<p>The cervix should be visualised at each smear test.</p> <p>Undiagnosed abnormal bleeding requires investigation.</p> <p>Abnormal cells may occupy only a small area of the transformation zone.</p> <p>Figure 4.24 Cancer of the cervix</p> 

<p>A vault smear</p> <p>There are occasions when it is advised that a smear should be taken even though the cervix has been removed along with the uterus at hysterectomy. This is what is called taking a vault smear. The commonest reason to continue screening in this situation is if the woman has had a hysterectomy because of abnormal cells that have micro-invaded or recurred following treatment.</p> <p>The upper end of the vagina must be inspected for any abnormal looking lesions and cells harvested from the area where the vaginal scar is visible. If the scar is not visible an extensive brush action sweeping in a <u>clockwise direction</u>, where possible, five times is advised.</p>	<p>Figure 4.25 Vault</p> 
--	--

Message for the woman

The biggest risk factor for cervical cancer is never having had a cervical smear screening test. Cervical screening endeavours to pick up abnormal cells on the cervix that if left untreated may turn cancerous.

The presence of genital warts does not necessitate more frequent smear tests.

4.2D The Cervical Cytology Form

THE CERVICAL CYTOLOGY FORM	KEY POINTS
<p>What is the Cervical Cytology Form?</p> <p>Over one million women will be eligible for screening in the National Cervical Screening Programme. The Cervical Cytology Form is designed to ensure that the right woman gets the right result. Complete, current and accurate demographic information is necessary and all information recorded in the Cervical Cytology Form must be legible. Arrangements are presently being made to allow for electronic form filling.</p> <p>CervicalCheck currently holds records on all women who have had smears within the Programme. This information is available through the electronic link to the laboratory which allows for each woman's smear history, once on the system, to be easily retrieved should she move location or change smartaker.</p>	<p>Consequences of inaccuracies on the Cervical Cytology Form:</p> <ul style="list-style-type: none"> • Waiting time for results increase • Women get tagged with inaccurate past medical history that affects management • Women with cervical changes go untreated • Women receive inaccurate results • Increased risk of litigation

<p>Demographic details - accuracy of information</p> <p>There is a minimum data set of information required when completing the Cervical Cytology Form, which helps to match the right results to the right woman. The CervicalCheck Minimum Dataset is as follows (see also Section 1.5):</p> <ul style="list-style-type: none"> • DOB • Forename • Surname at birth • Mother's maiden name • PPS Number • Middle names • Surname • Address • Phone number <p>The address on the Cervical Cytology Form is the address to which all letters and contacts with the woman are directed. Women and smartakers need to understand the importance of informing the Programme if an address changes.</p>	<p>Accurate information is vital for identification.</p> <p>The contact phone number on the Cervical Cytology Form can be useful in cases where there is any doubt about the woman's identity.</p> <p>Women can use the Freephone information line to inform the Programme of any changes to their personal details.</p> <p>Demographic details should be printed one letter per box.</p>
---	---


4.2D The Cervical Cytology Form contd.

THE CERVICAL CYTOLOGY FORM	KEY POINTS
<p>Personal Public Service Number (PPS No.)</p> <p>The success of the delivery of the screening Programme requires the use of the unique identifier, the Personal Public Service Number (PPS No.). It is vital that all smartakers understand the importance of the unique identification number to ensure accuracy in the follow through of a woman's smear processing stages and that all women should have a PPS number.</p>	<p>PPS Numbers can be found from the following:</p> <ul style="list-style-type: none"> • Social Welfare Office • NCSS/ CervicalCheck information line or invitation letter • On GMS Medical Card or Drugs Cost Subsidy Card
<p>Using the Information Line</p> <p>Smartakers can use the information line to access smear information, PPS Numbers and eligibility about women presenting for smear tests, etc.</p> <p>Women can use the line to make changes to their demographic details and check issues related to their smear tests.</p>	<p>The Freephone information line is open from 9.30am – 5.00pm weekdays with the exception of bank holidays.</p> <p>Clinical details are not made available to women via this information line. Clinical information is only available from the smartaker.</p>
<p>Pre-screening & form filling</p> <p>The key question the smartaker needs to ask at the pre-screening stage is whether the woman has ever been sexually active. She will need regular smears if she answers positively. Questions about a woman's sexual history and the number of partners are irrelevant and need not be asked.</p> <p>Her personal identity and contact details should then be entered on the Cervical Cytology Form at this point.</p>	<p>It is important that the woman's details are not copied from a previous form or notes without checking with the woman that her details are correct. It is also important to obtain a contact telephone number for the woman.</p> <p>The Cervical Cytology Form is the only form in use when taking a screening smear within the CervicalCheck Programme.</p> <p>The Cervical Cytology Form is about:</p> <ul style="list-style-type: none"> • Connecting the 'right woman' with the 'right result' • 'Legible' information • 'Correct' information • 'Complete' information


See sample of completed Cervical Cytology Form in Appendix

4.2D The Cervical Cytology Form contd.

THE CERVICAL CYTOLOGY FORM	KEY POINTS
<p>Information for women & consent (See also Section 4.2F & Section 6)</p> <ul style="list-style-type: none"> • Clear simple information is readily available • Research evidence indicates that information which women can take with them is valuable • Leaflets designed for the woman are of help to both the smartaker and the woman and will assist in making the screening a more positive experience for women <p>Consent (see Section 6)</p> <p>There are a number of aspects regarding consent:</p> <ul style="list-style-type: none"> • Consent to use personal information so that it can be received and retained • Consent to use medical information arising out of the smear test as necessary and • Consent to retain and use the slide / vial for audit and research 	<p>The woman participating in the screening programme must sign consent on the Cervical Cytology Form each time she has a smear test through the Programme.</p>




<p>History taking</p> <p>Questions to ask the woman that are useful and which will assist in ensuring her comfort, and in focusing the smartaker on each individual smear:</p> <ol style="list-style-type: none"> 1. Any abnormal bleeding: <ul style="list-style-type: none"> • Post-coital bleeding (PCB)? • Inter-menstrual bleeding (IMB)? • Post-menopausal bleeding (PMB)? 2. Any unusual vaginal discharge? 3. Any pain or discomfort with sexual intercourse? 	
---	--



4.2D The Cervical Cytology Form contd.


CLINICAL DETAILS	KEY POINTS
<p>Date of smear test The date of current smear test.</p>	<p>It is vital to record the date of smertaking.</p>
<p>Relevant clinical detail required (Boxes to tick on Form)</p> <ul style="list-style-type: none"> • Cervix visualised • LMP • HRT • Pregnant • Post colposcopy smear • IUCD • Post menopausal 	<p>This information helps the cytologist to make an accurate recommendation when viewing cells at cytology.</p>
<p>Cervix visualised The cervix must be visualised in its entirety.</p>	<p>It is the responsibility of the smertaker to visualise and assess the cervix at every smear test.</p>
<p>Why information related to LMP is required Endometrial cells are normally present in the first 12 days of the cycle. Outside these days or in post-menopausal women, they may be considered abnormal and are reported by the cytologist. The problem is that endometrial cells can look very similar to high grade dyskaryotic cells on the stained smear and hence the LMP can help the cytologist to decide whether they are abnormal cells or endometrial cells.</p>	



4.2D The Cervical Cytology Form contd.

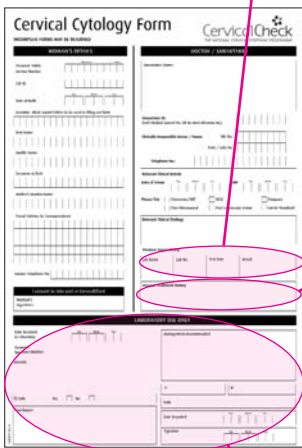
CLINICAL DETAILS	KEY POINTS
------------------	------------

<p>Why information about the woman's hormonal status is required</p> <p>Eversions may be present if a woman is using the oral contraceptive pill (OCP) or replacement oestrogen. There may be changes in the appearance of the squamous cells when women are using Hormone Replacement Therapy (HRT). The sample cytology may appear similar to a mid-cycle ovulatory slide. Women on HRT can shed endometrial cells which may be present on the cervical smear and hormonal information will help the cytologist exclude dyskaryotic cells.</p> <p>The presence of IUCD/coils should be noted as there is a greater likelihood of inflammatory cells including actinomycosis which may give rise to cellular changes that mimic dyskaryosis.</p>	<p>All hormonal methods including:</p> <ul style="list-style-type: none"> • Nuva Ring • Implanon • Depo-provera • Evra • OCP and • HRT <p>should be recorded by ticking the hormonal box.</p> <p>A Mirena coil is an intrauterine system and a hormonal method. It does not interfere with the smear test.</p>
--	--



<p>Relevant clinical findings (free text box on Form)</p> <p>Describe what you see at the time of smearing on the referral form.</p> <p>Discharge warts, polyps may be of relevance to the cytologist and should be recorded in the clinical findings box.</p>	<p>Suggested terms to describe the cervix include:</p> <ul style="list-style-type: none"> • Normal looking cervix • Eversion • Contact bleeding <p>The laboratory recommendation for clinically described 'suspicious cervix' is referral for colposcopy even if the smear result is negative.</p>
---	---

4.2D The Cervical Cytology Form contd.



CLINICAL DETAILS	KEY POINTS
<p>Previous smear history</p> <p>Most women accessing the Programme will have a previous smear history. In the course of an organised screening programme, the result and management of information on each woman who participates in the Programme will be compiled. In order for the laboratory to make a recommendation the following minimum dataset to be entered in the appropriate part of the Cervical Cytology Form:</p> <ul style="list-style-type: none"> • Previous two smear results if available (whether normal or abnormal) • Date of the last smear • Laboratory where processed (on result form) • Laboratory numbers were available (on result form) • Information and details of abnormal smears in the past (especially in the last 10 years), including date and laboratory accession number if known 	<p>It is important that the smertaker checks, as far as possible, the woman's relevant clinical history by referring to her records and documents the smear history on the Form.</p> <p>Laboratory recommendations could be inappropriate without complete information.</p>
<p>Previous treatment history</p> <p>Information relating to any previous colposcopic treatment of the cervix should be recorded where available.</p>	<p>The danger of developing cancer remains higher in those who have a treatment for CIN 3.</p> <p>Smertakers are advised to follow the discharge colposcopy recommendations for request smears.</p>
<p>The Cervical Cytology Form and the laboratory</p> <p>Each vial reaching the laboratory must be accompanied by a corresponding Cervical Cytology Form.</p> <p>The laboratory will reject the sample if it cannot match the details on the form to the details on the sample.</p>	<p>It is recommended that the samples are posted to the laboratory on the day of the test.</p>

Laboratory recommendations are dependant on cells presented, on the clinical findings and the previous smear history of each woman. Diligent completion of the Cervical Cytology Form will help the cytologist make an informed assessment of each smear.

4.2E Anatomy and physiology

The cervical epithelium is made up of the multi-layered squamous epithelium on the ectocervix and the thinner columnar epithelium on the endocervix. The transformation zone is the epithelium proximal to the squamo-columnar junction, where the epithelium is undergoing change from columnar to squamous epithelium known as squamous metaplasia. This vulnerable area is known as the transformation zone where CIN changes tend to occur. The squamo-columnar junction is at the junction between the squamous epithelium and the endocervical columnar epithelium.

The position of the transformation zone varies during a woman's lifetime. At puberty, the transformation zone lies at the external cervical os. Hormonal changes at puberty and in pregnancy cause the cervix to change shape and the lower part of the endocervical canal becomes everted. After puberty and before the menopause, a woman's squamo-columnar junction usually lies on the ectocervix. In post-menopausal women there is a reduction in the size of the cervix. The squamo-columnar junction comes to lie within the endocervix.

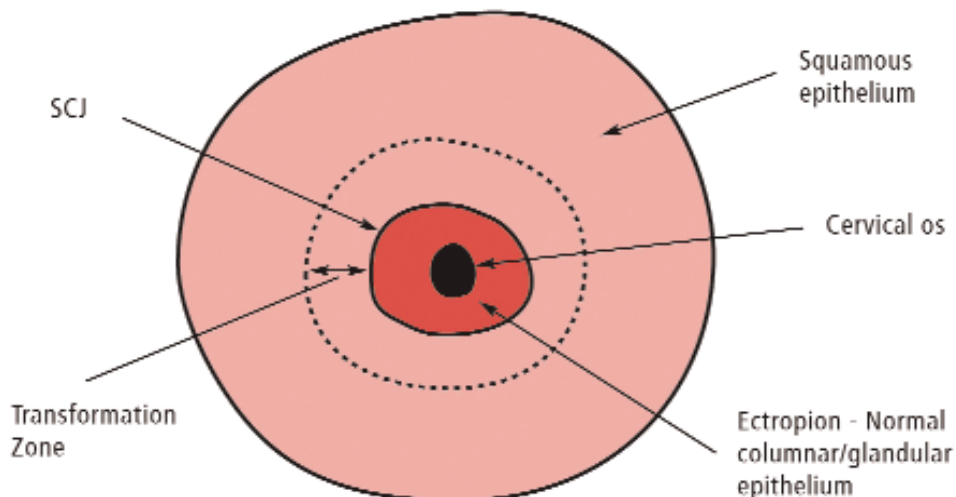
Acidic fluid within the vaginal secretion break downs the migrating columnar epithelium, which is replaced by squamous cells. This is a normal process called metaplasia. Immature metaplastic cells i.e. those in the process of changing, are more sensitive to carcinogens than mature cells.

See Sections 3 & 5 for further information on CIN and the Classification Systems

Most cancers of the cervix develop from abnormal epithelial changes. Early changes are called Cervical Intraepithelial Neoplasia (CIN).

Microscopic examination of cells scraped from the surface of the epithelium of the cervix can determine whether CIN is present. CIN may occupy only a small area of the transformation zone.

Figure 4.26 Cervical Ectropion



4.2E Anatomy and physiology contd.

Figure 4.27 The transformation zone

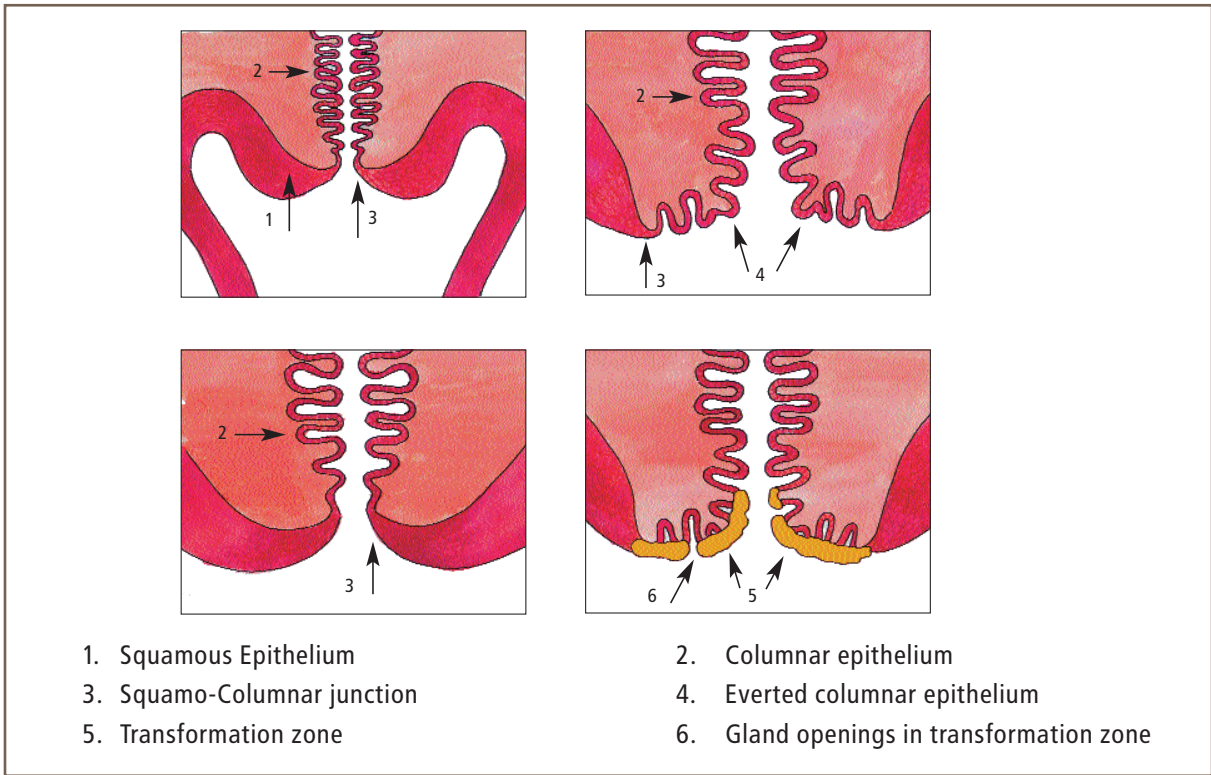
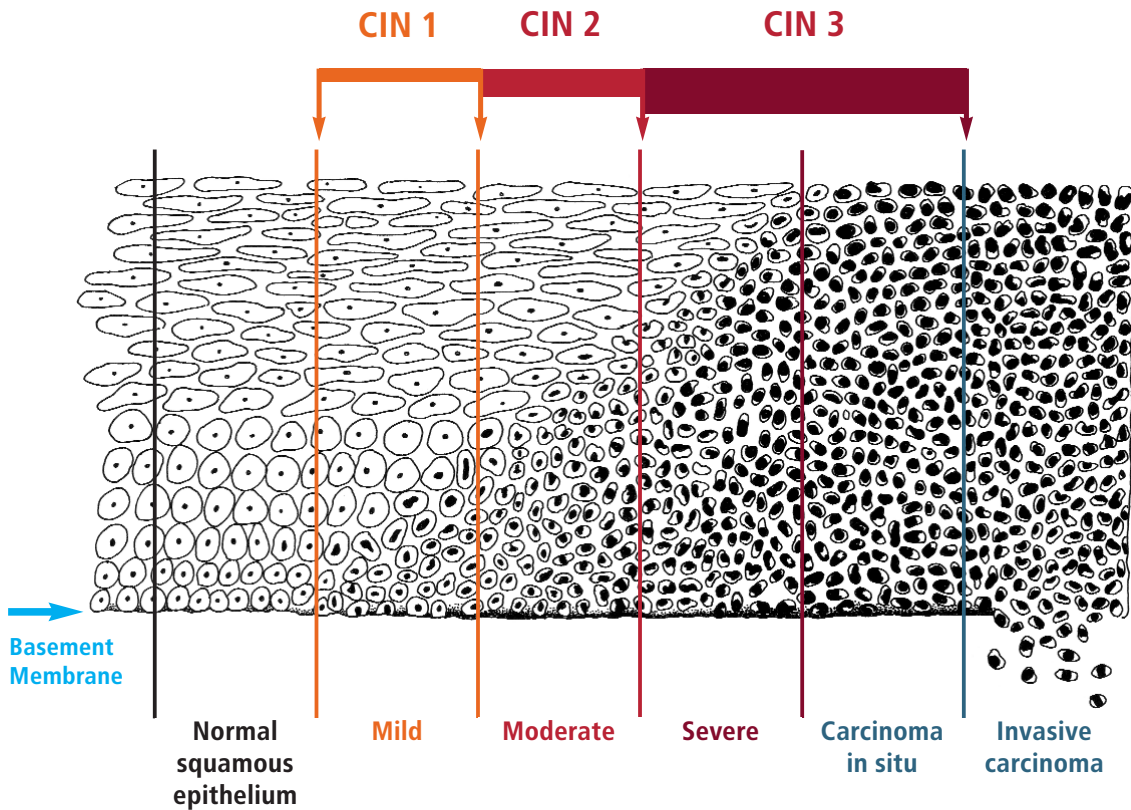



Figure 4.28 Cervical Intraepithelial Neoplasia



4.2F Consultation

COUNSELLING & CONSENT	KEY POINTS
<p>Counselling</p> <p>Women having a cervical smear taken should be counselled before, during and after the procedure. The woman's understanding of the test and her concerns about its implications need to be fully addressed. Clear language should be used. It is important to check with the woman that she understands all the information provided.</p> <p>It must be clear to all women having the test what a cervical smear does not detect, and that the test relates only to the cervix. No information is obtained about the other pelvic organs. Women should be advised that normality of the ovaries and uterine functions cannot be assumed following a normal smear result.</p> <p>Women should be given an estimated time in which they may expect to receive the result of their smear and informed that CervicalCheck will send a notification of their result to the woman at the address on the Cervical Cytology Form. Details will be provided by their smearer or doctor with clinical responsibility.</p>	<p>Figure 29. Information for women</p>  <p>See Section 6 on key information that smear takers should provide to women.</p> <p>A charter of women's rights is available on the CervicalCheck website.</p> <p>It should be emphasised that the smear test is not a test for cancer. It is a screening test only.</p>
<p>Results</p> <p>Each woman must be given the opportunity to discuss the result of her test and its implications and should be advised that an appointment can be made with the smearer or the doctor with clinical responsibility free of charge to her. Each woman should fully understand the significance of the test result. Care should be taken not to generate unnecessary anxiety.</p> <p>All counselling related to the smear must be readily available to the woman. Women undergoing colposcopic assessment and treatment are entitled to counselling from their smearer. For CervicalCheck registered smear takers, all such counselling is included in the smearer's contract fee so no charge should be levied.</p>	<p>'Normal' results can be discussed by phone. Face to face consultation for all other results is recommended, with adequate time allowed for questions and explanation (see Section 5 on communicating results).</p> <p>A counselling session should ensure privacy, confidentiality, trust and sensitivity.</p>

4.2F Consultation contd.

COUNSELLING & CONSENT	KEY POINTS
<p>Informed consent Informed consent must be obtained without duress. Consent to have the smear taken is implicit when the woman allows the test to occur. However, this should only occur after a full explanation as outlined earlier.</p> <p>Written consent is for permission to transfer information recorded on the CervicalCheck Cervical Cytology Form by the smertaker to a third party. This is a legal requirement. CervicalCheck will use the information for the purposes of providing each woman with cervical screening services, including future call and recall. The information will also be used in auditing, reviewing and monitoring the delivery of the Programme. See Section 4.2D above.</p> <p>Should any woman decline to have her details sent to the CervicalCheck Office, she should not sign the consent form. CervicalCheck will not cover payment for this type of smear or the laboratory processing fee.</p>	<p>The 'Information for women' explicitly informs women that they are consenting to all aspects of CervicalCheck, including research and audit. See section 4.2D above. However, women will be given the choice not to participate in any research projects conducted by CervicalCheck.</p> <p>See Section 6 for further details on Informed Consent.</p>

4.2G Environment and Equipment

ENVIRONMENT	KEY POINTS
<p>Infection control Some women may not attend for smear tests due to their concerns of acquiring an infection in the course of a test. For them, the risk of infection outweighs the risk of cervical cancer.</p>	<p>It is important that women are assured of a safe environment to ensure screening participation.</p>
<p>Prevent cross infection between patient & smertaker The smertaker's hands should be washed before and after any duty that involves close contact with the patient. Disposable seamless gloves should be used and changed between patients.</p>	<p>The vagina and cervix is not a sterile area.</p>

4.2G Environment and equipment

ENVIRONMENT	KEY POINTS
<p>Prevent contamination of the environment</p> <p>There should be separate sinks for hand washing and washing instruments. There should be paper towels for hand drying. Lever taps and soap dispensers are preferable.</p> <p>Objects touched during the course of the procedure e.g. lamp, should be cleaned with a dry paper towel.</p> <p>Instruments must be cleaned, rinsed and dried; used/non-sterile instruments should be kept separate from clean instruments. Disposable paper sheets should be used and changed between patients. Couches should be cleaned regularly with soap and water.</p>	<p>It is essential that used instruments and equipment are disposed of safely as clinical waste.</p>
<p>Single-use instruments and sterilisation</p> <p>There are no nationally approved standards for the sterilisation of surgical instruments in general practice in Ireland.</p> <p>It is recommended that single use speculae are used when smearing in primary care. Packages must only be opened at the time of smearing. The speculum must not be reused. The speculum should be disposed of in clinical waste.</p> <p>Sterilised speculum must be sterilised according to best practice (NHS) sterilisation guidelines.</p> <p>Where single devices cannot be used, the use of central sterilisation units is recommended. Re-usable speculum processed via an accredited sterilisation unit can be used.</p> <p>For in-house sterilisation, careful attention is required in the use and maintenance of sterilising equipment. Speculae must be thoroughly cleaned before sterilising. Operators of bench top sterilisers should be trained and manufacturers' instructions should be followed with care. Records should be maintained on the testing of such equipment.</p>	<p>Sterilising equipment for use during cervical screening procedures need to guarantee that speculae are sterile when used.</p> <p>Sterilised instruments must be stored in a clean dry place.</p> <p>Chemical cleaners are for hand use only and not for clinical use.</p>

4.2G Environment and equipment contd.

REQUIRED EQUIPMENT	KEY POINTS
<p>Hand washing facilities / chemical cleaning liquid The smertaker's hands should be washed or chemically cleaned before and after any duty that involves close contact with the patient.</p>	
<p>Paper towels Paper towels should be used for hand washing and for handling and positioning of the light.</p>	See Section 4.2B above.
<p>Illumination Good lighting is essential for cervical screening procedures. An adjustable halogen spotlight provides one of the better sources of illumination and a speculite can be used.</p>	See Section 4.2B above.
<p>Examination couch The examination couch should be placed in a position to allow easy vaginal examination with the woman in either the left lateral or dorsal position. It should allow ease of access for women with a physical disability.</p>	See Section 4.2B above.
<p>Gloves Vinyl or latex disposable gloves are recommended.</p>	Some women are allergic to latex rubber.
<p>Ballpoint pen Label the vial with a pen.</p>	
<p>Cervical Cytology Forms The CervicalCheck Cervical Cytology Form is a two-leaf form.</p>	See Section 4.2D
<p>Sheet, blanket, pillow A disposable sheet, pillow and blanket cover should be used for patient comfort.</p>	
<p>Steriliser if using reusable speculae A systematic and documented system must be in place that follows manufacturers' guidelines.</p>	See 'Environment' above in this section.

4.2G Environment and equipment contd.

<p>Speculum At least three different sizes of bivalve vaginal speculum (Cusco's speculum) should be available: small, medium, and large. A very small speculum (virgin speculum) and a long-bladed narrow speculum may occasionally be needed.</p>	<p>See Figure 4.8, Section 4.2B. Specula packaging should be opened immediately prior to procedure to avoid contamination.</p>
<p>Sampler – Cervex-Brush® The plastic brush is used in liquid based cytology.</p>	<p>See Figure 4.2, Section 4.2A</p>
<p>Liquid-Based Cytology (LBC) vial A vial is the transport medium for liquid-based cytology.</p>	<p>See Figure 4.1, Section 4.2A</p>
<p>Soluble lubricant- KY Jelly A soluble lubricant such as KY Jelly should be used carefully if the vagina is very dry. Care must be taken to use only a little on the shaft and avoid use at the tip of the speculum.</p>	
<p>Swabs Chlamydia swabs and charcoal swabs should be available for the evaluation of infectious discharge.</p>	<p>See Section 4.2C above</p>
<p>LBC transport boxes LBC transport boxes are supplied by the LBC supplier.</p>	<p>See Figure 4.6, Section 4.2A</p>
<p>Waste disposal bags Clinical waste needs to be disposed of with care, especially used disposable speculums and samplers.</p>	
<p>A pedal bin A pedal bin helps to avoid contamination of the environment.</p>	
<p>Patient information leaflets A range of information leaflets for women are available from CervicalCheck.</p>	

4.3 Managing difficulties that may arise when taking a smear

4.3.1 Anticipating difficulties

Smear taking is a clinical skill that needs to be acquired with experience and even the most experienced smertaker may encounter difficulties in the course of a procedure when taking a smear. If such difficulties are anticipated in advance and given due consideration, there is a greater possibility that many can be managed and the smear will be taken competently.

It is important that the smertaker is decisive and above all relaxed when a difficulty arises. It may be useful to explain the difficulties to the patient so that the patient's fears are dispelled and to allow the smertaker more time to take the smear. This approach can be applied to all types of problems that can arise when taking a smear to ensure the best outcome. The following are examples of typical problems that cause most difficulty for smertakers and some solutions are offered.

4.3.2 The anxious, tense patient

The key in dealing with the anxious and tense patient is to help her to relax. The smertaker should reassure her that the procedure can be stopped at any time at her request. Giving the woman control of the situation will ensure the best chance of a successful outcome. Deep breathing can be suggested and a chaperone (see Section 4.2A) may help. The smertaker should offer to talk the patient through the steps of the procedure and should enquire whether the woman has particular fears.

The woman may worry that the procedure will be uncomfortable if she suffers from arthritis of her hips or chronic lower back pain. The smertaker should explain that an alternative position, if necessary, can be arranged and the left lateral position should be considered (see Section 4.2B above).

Prescribing an anxiolytic prior to the procedure in the absence of any contraindications can be considered if the patient is extremely anxious.

4.3.3 Patient becomes upset during the procedure

Sometimes a woman may appear to be comfortable about having a smear initially and then become upset during the procedure. When this situation arises, the smertaker must stop and try to calm the woman. The smertaker must be aware that taking a smear is a very intimate examination and may trigger sensitive issues like sexual abuse, past or present, partner impotence or lack of libido. If possible, the test should not be deferred particularly when it has elicited such strong emotions.

4.3.4 Difficulty in visualising the cervix

This is the most common problem that arises for smertakers and can give rise to an unfortunate circle e.g. the smertaker is unable to find the cervix, the patient becomes more anxious, she contracts her pelvic floor muscles, the cervix becomes more difficult to locate and the smertaker becomes frustrated. The cervix will become easier to find if the following adjustments are made.

4.3 Managing difficulties that may arise when taking a smear contd.

Adjustments to address difficulties in visualising the cervix

Key points:

1. Get the woman to lie flat. If the head-rest of the couch is elevated it can cause the pelvis to become tilted thus making the cervix less visible.
2. Elevate the pelvis. Place a folded towel under the gluteal region or get the patient to put her fist under the gluteal area.
3. Use the largest/longest speculum that is comfortable for the patient. Often the cervix is not visualised because the speculum is too short. Consider the woman's size, parity and degree of relaxation when choosing the speculum. It is important to angle the speculum towards the patient's coccyx. It is helpful to allow a little time after passing the speculum to allow the woman to relax. Do not open the speculum until it is fully inserted. Opening and closing the speculum slightly, rocking it from side to side and changing the angle of insertion may help to bring the cervix into view.
4. If the cervix is still not visible check the notes to ensure that the woman has not had a total hysterectomy. Having clarified that she does have a cervix, a pelvic examination can be done gently to locate the position of the cervix, being careful not to disturb the cells of the cervix prior to sampling. Perhaps the cervix is anteverted or retroverted thus making it difficult to locate which will become clear on careful pelvic examination.
5. Sometimes the cervix is obscured by flaccid vaginal walls. If using a longer wider speculum does not hold back the vaginal walls, the following procedure can be helpful. Cut a disposable rubber/latex glove 1cm from the top of the thumb digit; pull the open ended rubber thumb digit over the closed speculum; pass the speculum with the remainder of the disposable glove hanging out of the vagina; as the speculum is opened, the glove digit holds back the flaccid vaginal walls and allows the cervix to come into view.
6. In patients who are heavy or with poor range of movement of their hips e.g. with M.S. or arthritis, the left lateral position may be more comfortable. It is important that a full explanation is given to the patient and this position is only adopted with their consent.
7. The cervix can be obscured by excess mucus. To inspect the cervix fully, this mucus may have to be removed. It is important that the cells of the cervix are not disturbed prior to sampling. Very gently place the non bristle end of the Cervex-Brush® into the mucus at the outer edge of the cervix. Rotate the brush into the mucus and the mucus will lift off. Now with the bristle end of the Cervex-Brush®, take the smear, lifting off the undisturbed cells on the cervix and transferring them to the vial.

4.3 Managing difficulties that may arise when taking a smear contd.

4.3.5 Vaginal discharge

The smertaker may notice a vaginal discharge. A profuse/ odorous/ discoloured/ yellow or green/ or blood stained vaginal discharge suggests infection. If the smertaker proceeds to take a smear, swabs should be taken after the smear. If contact bleeding occurs, the smertaker should consider Chlamydia and test appropriately.

4.3.6 Anatomical variation

Smertakers must be familiar with the range of physiological and anatomical variations of the vulval area. The following can cause concern if not recognised:

- Intact Hymen
- Narrow Introitus
- Cystocoele/ Rectocoele
- Long labia
- Bartholin's Cysts
- Vaginal scarring e.g. post-episiotomy, female genital cutting, etc.
- Vaginal pessary rings may be in situ (smertaking may proceed)

4.3.7 Medical conditions

Clinical signs of medical conditions may be observed while taking a smear. It may not be appropriate to deal with these during the smear consultation, but it is important that arrangements are made to follow them up at another time. Incidental findings of alopecia or psoriasis, pubic lice, vulval ulcerated lesions or genital warts may be observed.

Women who are immuno-compromised may need more frequent screening. This is currently not facilitated by the CervicalCheck call/ recall system.

4.3.8 Sensitive sexual issues

All women between the ages of 25 and 60 will receive an invitation letter to have a smear. For some women e.g. virgins, having a smear test is not appropriate, because they have never had sexual intercourse. Cervical cancer is rare in women who have never being sexually active (Bankhead & Austoker, 2003), and the smertaker should not proceed if the hymen is intact. Participation in screening can be deferred, and the woman informed that if she becomes sexually active, she should have cervical smears.

Vaginismus may make it impossible to pass a speculum of any size. It is important to explain to the woman that this is a medical condition which responds extremely well to appropriate therapy, and that once it has been resolved it is important that she returns to have a smear.

4.3.9 Women who have sex with women (WSW)

Cervical screening recommendations do not differ for WSW/ lesbian women regardless of their history of sex with men. Cervical neoplasia and CIN lesions can be found in WSW who report no history of sex with men. Transmission of HPV requires only skin to skin contact. Furthermore sexual practices among WSW could potentially allow for intra-vaginal deposition of HPV both through digital-vaginal contact and shared sex aids. Studies show that most WSW (53-99 per cent) have had sex with men and that many (21-30 per cent) continue to have sex with men. Among these women, acquisition of HPV from male partners presumably occurs at a rate per contact similar to that of the heterosexual population. Women infected via this route could serve as a source for subsequent viral transmission to their female partners (Marrazzo et al, 2001).

APPENDIX 4

* Fictional demographics used for illustration purposes.

Cervical Cytology Form



INCOMPLETE FORMS MAY BE RETURNED

WOMAN'S DETAILS

Personal Public Service Number
 Numbers: 6 3 7 0 1 4 8 5
 Letters: T

CSP ID: 4 1 0 5 2

Date of Birth
 Day: 2 4, Month: 0 5, Year: 7 6

Surname: Block capital letters to be used in filling out form
 M C N A M E E

First Name: S A R A H

Middle Name: J A N E

Surname at Birth: D R I V E R

Mother's Maiden Name: C L E A R Y

Postal Address for Correspondence
 6 C L O S S E Y D R I V E
 M U N G R E T
 L I M E R I C K

Contact Telephone No.: 0 8 1 4 3 1 3 2 0

I consent to take part in CervicalCheck

Woman's Signature: Sarah McNamee

DOCTOR / SMEARTAKER

Smertaker Name: Angela Fahy
 Address: Meadowvale Medical Centre
 Main Street
 Broadvalley
 Co Limerick

Smertaker ID: 0 0 0 3 6 9 4 2
(derived from Medical Council or An Bord Altranais No.)

Telephone No.: 0 8 1 4 0 6 4 1 2

Clinically Responsible Doctor ID or Clinic ID: 0 0 8 3 1 7 4 9
(derived from IMC No.)

PCRS / GMS No.: 0 0 0 9 6 4 2 6

Relevant Clinical Details:

Date of Smear: Day: 0 8, Month: 0 7, Year: 0 8
 LMP: Day: 2 3, Month: 0 6, Year: 0 8

Parity: _____

Please Tick: Hormones/HRT, IUCD, Pregnant
 Post Menopausal, Post Colposcopy Smear, Cervix Visualised

Relevant Clinical Findings

Large eversion noted
 Contact bleeding

Previous Smear History

Lab Name	Lab No.	Test Date	Result
UCHG	1214/0	11/1/05	Negative

Previous Treatment History

LABORATORY USE ONLY

Date Received in Laboratory: Day: , Month: , Year:

Accession Specimen Number:

Barcode

Management Recommended

1°: , 2°:

Path

Date Reported: Day: , Month: , Year:

Signature: Day: , Month: , Year:

TZ Cells: Yes No

Final Report

CS/F/PA17 Rev 5

References and further reading

British Society for Clinical Cytology (2003): *Taking Cervical Smears*. BSCC, London.

Ferenczy, A., Wright, T.C, (1994): Ch. 5: *Anatomy & Histology of the Cervix*. In Blaustein's *Pathology of the Female Genital Tract*, ed. Kurman, r.j., 4th Edition, Springer-Verlag: pp 185-201.

Health Equipment Information (1988): *An Evaluation of Portable Steam Sterilisers for Unwrapped Instruments and Utensils*. HMSO, UK.

Marrazzo, J.M., Koutsky, L.A., Kiviat, N.B., Kuypers, J.M., Stine, K,(2001): *Pap Test Screening and Prevalence of Genital HPV Among Women Who Have Sex With Women*. American Journal of Public Health, 2001 91: 947-952.

Philips, P. *Issues Relating to the Use of Disposable and Reusable Speculum*. Surgical Material Testing Laboratory, UK.

Rosenthal, J., Rymer, J., Jones, R., Haldane, S., Cohen, S., Bartholomew, J.(2005): *Chaperones for Intimate Examinations: Cross Sectional Survey of Attitudes and Practices of General Practitioners*. BMJ 2005;330;234-235.

Vooijs, G.P., Van der Graaf, Y., Elias A.G. (1987): *Cellular Composition of Cervical Smears In Relation to the Day of The Menstrual Cycle and the Method of Contraception*. Acta Cytol., 31, 417-26.

Welsh Health Estates (2001): *Guidance for the Application, Use, Maintenance and Testing of Benchtop Steam Sterilizers in the Welsh NHS*, NHS, Oct 2001.

Notes

Notes